

# Bone formation in a long bone defect model using a platelet-rich plasma-loaded collagen scaffold

Michael R. Sarkar<sup>a</sup>, Peter Augat<sup>b</sup>, Sandra J. Shefelbine<sup>b</sup>, Sandra Schorlemmer<sup>b</sup>,  
Markus Huber-Lang<sup>a</sup>, Lutz Claes<sup>b</sup>, Lothar Kinzl<sup>a</sup>, Anita Ignatius<sup>b,\*</sup>

<sup>a</sup>Department for Trauma, Hand and Reconstructive Surgery, University of Ulm, Ulm D-89070, Germany

<sup>b</sup>Institute for Orthopaedic Research and Biomechanics, University of Ulm, Helmholtzstrasse 14, Ulm D-89081, Germany

Received 25 July 2005; accepted 31 October 2005

Available online 22 November 2005

## Abstract

Platelet-rich plasma (PRP), a platelet concentrate made of autogenous blood, has been used in recent years to improve bone defect healing particularly in maxillofacial reconstructions. The aim of the present study was to assess the effect of PRP on new bone formation in a critical diaphyseal long bone defect. A critical size defect (2.5 cm) in the tibial diaphysis of 16 sheep was supplied either with autogenous PRP in a collagen carrier or with collagen alone (controls). Platelets were enriched about 3.5 fold compared to normal blood in the PRP. After 12 weeks, the explanted bone specimens were quantitatively assessed by X-ray, computed tomography (CT), biomechanical testing and histological evaluation. Bone volume, mineral density, mechanical rigidity and histology of the newly formed bone in the defect did not differ significantly between the PRP treated and the control group, and no effect of PRP upon bone formation was observed. It was suggested that PRP does not enhance new bone formation in a critical size defect with a low regenerative potential. Such bone defects might require more potent stimuli, e.g. combinations of functional biomaterials or autografts, precursor cells or osteoinductive growth factors.

© 2005 Elsevier Ltd. All rights reserved.

**Keywords:** Bone regeneration; Bone defect; Platelet-rich plasma; Collagen; Animal model; Sheep

## 1. Introduction

Large bone defects resulting from trauma, tumors, osteitis, implant loosening or corrective osteotomies require surgical therapy, because spontaneous regeneration is limited to relatively small defects. Currently, transplantation of autografts or allografts, mineral bone substitutes and callus distraction are the most commonly used techniques for skeletal reconstruction, each of them having important limitations regarding e.g. availability and biological or biomechanical reasons [1,2]. Therefore, osteoinductive stimulation of bone formation has received increasing interest. Both demineralized bone matrix and growth factors have been used in numerous experimental and clinical defect situations [3]. Growth factors influence

chemotaxis, differentiation, proliferation and synthetic activity of bone cells, thereby regulating physiological remodelling and fracture healing. Numerous growth factors, such as bone morphogenetic proteins (BMPs), platelet-derived growth factor (PDGF), transforming growth factor- $\beta$  (TGF- $\beta$ ), and insulin-like growth factors (IGF) have a stimulating effect on bone defect healing by inducing chemotaxis, proliferation, and differentiation of osteoblasts and their precursors [3,4]. BMP-7 has already been tested successfully in clinical studies on tibial nonunions and fibular defects [5,6]. However, little is known about suitable combinations, concentrations, and application time points of various growth factors during bone defect healing.

An easy and more physiological way of application of growth factors to bone defects is via the use of platelet-rich plasma (PRP), a thrombocyte concentrate made of autogenous blood. Thrombocytes are among the first cells at the site of an injury and contain numerous growth

\*Corresponding author. Tel.: +49 731 50023489;  
fax: +49 731 50023498.

E-mail address: [anita.ignatius@uni-ulm.de](mailto:anita.ignatius@uni-ulm.de) (A. Ignatius).

factors, among them isomers of PDGF, TGF- $\beta_1$ , TGF- $\beta_2$ , IGF-I, IGF-II, and vascular endothelial growth factor (VEGF), however no BMPs [7,8]. Several previous investigations demonstrated a positive effect of PRP on wound healing [9–11]. A lot of studies have been performed to investigate the effect of PRP upon bone defect regeneration [7,12–18]. However, the results are controversial. Marx et al. used PRP for the reconstruction of maxillofacial defects in humans and found that PRP resulted in a quicker maturation of autogenous bone transplants and higher bone density [7]. Another prospective study also reported a positive effect of PRP in a similar defect situation [13]. Further clinical investigations suggest an osteogenic potential of PRP but did not include control groups [14,16,17] or could not identify any positive effect [19]. But not only clinical data are contradictory, experimental *in vivo* findings are also inconsistent. In a bone defect in the iliac crest of dogs PRP combined with demineralized bone powder enhanced bone formation around titanium implants [20]. In a rabbit skull model, however, PRP did not influence bone healing [12]. In a similar study in pigs PRP enhanced bone density temporarily when applied together with autograft but not in conjunction with a collagen scaffold containing additional osteoinductive proteins [18].

Because of the controversial results, there is still need for further research regarding the possible osteogenic potency of PRP particularly in diaphyseal bone. The objective of this *in vivo* study was therefore to investigate if PRP is effective in the reconstruction of diaphyseal long bone defects with low regenerative capacity. For this purpose, PRP-loaded collagen scaffolds were implanted in a critical size defect of the sheep tibia. New bone formation was investigated after 12 weeks by histological, radiological and biomechanical evaluation.

## 2. Material and methods

### 2.1. Preparation of platelet-rich plasma (PRP)

Autogenous PRP was obtained by modification of a technique established for human blood (Curasan, Kleinostheim, Germany). Prior to surgery, 80 ml of citrate blood were retrieved from the jugular vein of the sheep. The platelets were enriched by a two-step centrifugation process. First erythrocytes were sedimented with 840 g (2400 U/min, 10 min, Heraeus Labofuge 300, Kendro Lab Products, Langenselbold, Germany), then the supernatant containing plasma, leukocytes and platelets was sedimented at 1310 g (3000 U/min, 10 min) and thereafter resuspended in 0.4 ml of plasma. Samples of PRP and whole blood were analyzed in an automatic counter (ADVIA<sup>®</sup> 120, Bayer Diagnostics GmbH, Leverkusen, Germany) using veterinary software adapted to the size of sheep blood cells. The correctness of counter measurements had been ascertained by parallel manual counts in preliminary tests. 3.5 ml of PRP were loaded onto a scaffold (80 × 25 × 4 mm) made of bovine collagen type I (Lyostypt<sup>®</sup>, B. Braun, Aesculap, Tuttlingen, Germany) immediately before the insertion into the bone defect.

### 2.2. Animal model

The animal experiment was conducted following national regulations for the care and use of laboratory animals and approved by the German

Government (Regierungspräsidium Tübingen, no 708). 16 female merino sheep weighing 83 (70–97) kg with an age of 5.5–7.5 years were used for the study. The animals were randomly distributed to the PRP or the control group. Surgery was performed under general halothane anaesthesia and premedication with thiopental (Trapanal<sup>®</sup>, Byk Gulden, Netherlands). The medullary cavity of the right tibia was reamed to a diameter of 10 mm with a flexible medullary reamer (Synthes, Umkirch, Germany). In the middle of the tibia diaphysis the periosteum was removed and a standardized 2.5 cm full thickness defect was created with an oscillating saw. The defect was stabilized with a custom-made intramedullary nail (stainless steel) with two proximal and two distal locking screws. The nail diameter was 10 mm in the distal and 12 mm in the proximal tibia according to the anatomy of the tibia. To reduce stress at the screw/bone interface, the osteosynthesis was supplemented by a custom-made plate (stainless steel) at the medial side of the tibia. The PRP-loaded collagen sponge was placed around the nail in the defect zone and the wound was closed. The control group received collagen scaffolds without PRP. Immediately after the operation, the animals were allowed freedom of movement in individual stables. The fluorochrome markers calcein (10 mg/kg body weight, Calceingreen<sup>®</sup>, Synopharm, Barsbüttel, Germany) and tetracycline (25 mg/kg body weight, tetracycline hydrochloride, Caesar and Loretz GmbH, Hilden, Germany) were administered intravenously to label bone formation 4 and 8 weeks postoperatively, respectively. After a period of 12 weeks, the sheep were sacrificed and the operated and contra-lateral intact tibiae were removed.

### 2.3. X-ray analysis

Conventional X-rays in two planes were obtained immediately after surgery and again after 5, 7, 9 and 11 weeks. After 12 weeks an additional X-ray was performed on the explanted tibia. The degree of new bone formation during the healing period was estimated at four locations (medial, lateral, ventral and dorsal zone of the defect) using a semiquantitative score from 0 (no mineralized bone) up to at best 4 (complete bridging of the defect with mineralized bone). The other score values were defined as follows: few and isolated centers of ossification (1); more, but still discontinuous new bone formation (2); beginning, but incomplete bridging of the defect (3). The score values of the four locations were added to estimate the overall bone formation in the defect at a given time.

### 2.4. Biomechanical testing

As a measure of mechanical stability, the flexural rigidity of the tibia was evaluated using a non-destructive mechanical four-point bending test [21]. Before testing, metal implants were removed from the explanted tibiae. The intact contra-lateral tibiae were also mechanically tested. Briefly, both ends of the tibiae were fixed so that a 240 mm free length of bone remained with the defect area at the center. In a material testing machine (Zwick Z010, Zwick, Ulm, Germany), load was applied by two load supports (distance 50 mm) at a deflection rate of 6 mm/min up to a maximum force of 40 N. Intact tibiae were tested in a similar fashion but with a deflection rate of 2 mm/min. The deflection of bone was measured with a separate displacement actuator (MT25, Heidenhain, Traunreut, Germany). The bending load ( $F$ ) was recorded continuously versus sample deflection ( $d$ ). The bones were rotated 30° around the longitudinal axis and the protocol was repeated to determine bending rigidity in 12 loading directions. The values were averaged. From the load/deflection curve, the flexural rigidity ( $S_d$ ) was calculated according to

$$S_d = \frac{a^2(3L - 4a) F}{12 d}$$

with  $a$  is the distance between the lateral fixing points and the load support (95 mm),  $L$  the distance between the lateral fixing points (240 mm),  $F$  the load,  $d$  the sample deflection.

### 2.5. Computed tomography (CT)

The central part of the tibia diaphysis including the defect zone was assessed for apparent bone mineral density with a peripheral quantitative computed tomography scanner (XCT 960, Stratec, Pforzheim, Germany). Three measurements, which were averaged, were done in three sagittal planes through each bone defect. Additionally, the bone specimens were imaged with a  $\mu$ -CT scanner (Fan Beam  $\mu$ -Scope, Stratec, Pforzheim, Germany) at 100  $\mu$ m spatial resolution (Fig. 1). The three-dimensional (3-D) images were analysed with 3-D image analysis software (VGStudioMax 1.0, Heidelberg, Germany) to calculate the volume of the newly formed bone in the defect [22].

### 2.6. Histological evaluation

Immediately after CT analysis the bone specimens were processed for undecalcified histology. After embedding in methacrylate, 90  $\mu$ m slices were cut out of each bone specimen in longitudinal direction and surface stained by Giemsa. The formation of new tissue in the defect zone was examined under conventional light microscopy (Axiophot, Zeiss, Oberkochen, Germany). The relative distribution of bone, cartilage and fibrous tissue was measured histomorphometrically in seven predefined regions of interest using a point counting method with an eyepiece reticle at 20-fold magnification (Fig. 2). Two sections were evaluated for each bone defect. Finally, the slides were inspected under fluorescent microscopy (Axiophot, Zeiss, Oberkochen, Germany) to examine qualitatively which part of the bone had mineralized at the time of the fluorochrome marker application.

### 2.7. Statistics

The data are presented as median, minimum and maximum values (boxplots). To determine significant differences between the PRP and the control group the Mann–Whitney test for unpaired samples was used. To compare paired samples the Wilcoxon test for paired samples was used.

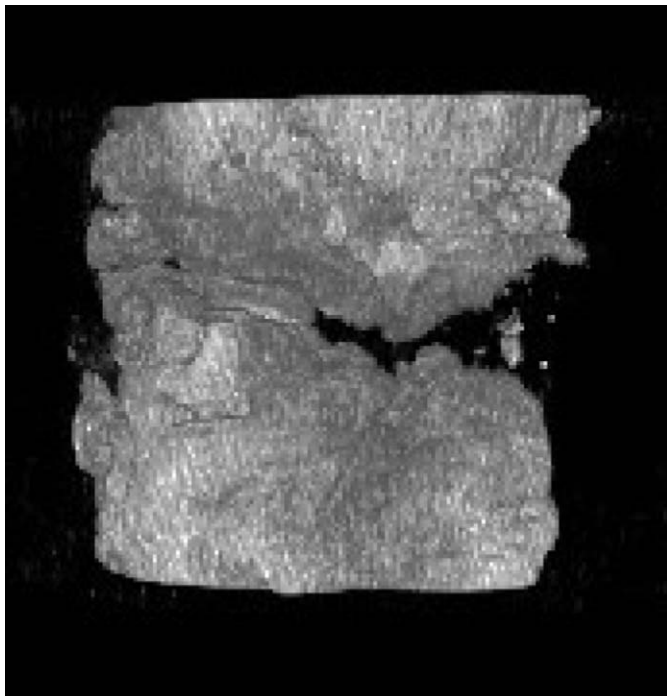


Fig. 1. Three-dimensional image of mineralized bone in a PRP-treated defect performed by the  $\mu$ -CT scanner at 100  $\mu$ m spatial resolution. The edges of the defect at the top and bottom of the image show intense new bone formation, however, there is no complete bridging of the defect.

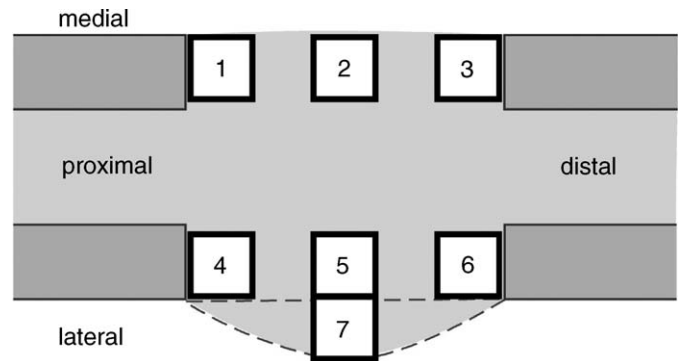


Fig. 2. Scheme of a histological slide with the bone defect and the callus in the tibia diaphysis. The relative distribution of bone, cartilage, and fibrous tissue was measured histomorphometrically in seven regions of interest. There was no periosteal callus formation on the medial side because the plate was attached to the bone here.

The level of significance was set at  $p < 0.05$ . Correlations were assessed by the Spearman rank correlation coefficient ( $r_{sp}$ ).

## 3. Results

One animal in each group was lost due to a fracture of the tibia near the holes of the locking screws. All other animals completed the study without any complications.

### 3.1. Platelet concentration in the PRP

Platelet concentrations in the native blood, which was collected just before the operation, varied interindividually between 191 and  $477 \times 10^3$  platelets/ $\mu$ l (median  $269 \times 10^3$ / $\mu$ l). In the PRP samples the platelet concentration was significantly higher ( $p < 0.02$ ). At an average a 3.5-fold, concentration increase could be achieved with relatively high interindividual variations (median  $953 \times 10^3$ / $\mu$ l, 423–1695  $\times 10^3$ / $\mu$ l).

### 3.2. X-ray evaluation

Evaluating the X-rays small areas of mineralization were visible after 5 weeks in some but not all defects of the control as well as the PRP group. Mineralization progressed continuously thereafter until the defects were nearly completely bridged (Fig. 3). Scoring the degree of mineralization in the medial, lateral, ventral and dorsal zone of the defects revealed the lowest mineralization at the medial side of the tibia between nail and plate (scores varying from 0 up to 3 after 12 weeks) and the highest at the lateral side (scores varying from 2 up to 4 after 12 weeks). There were no differences between the PRP and the control group comparing the degree of mineralization in the corresponding locations as well as the overall bone formation in the defect during the healing period after 5, 7, 9, 11, and 12 weeks.

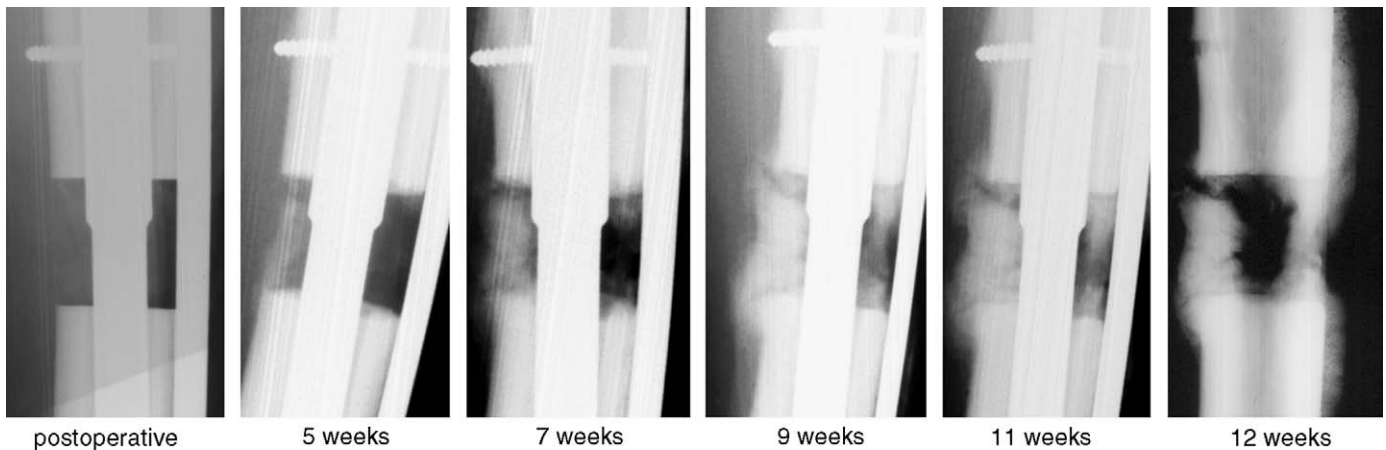


Fig. 3. X-rays of the defect area of a PRP-treated animal during the healing period of 12 weeks. Small areas of mineralization could be observed after 5 weeks. The lowest mineralization was found at the medial side between the nail and the plate.

### 3.3. Biomechanical results

All operated tibiae from the control and the PRP group revealed a significantly lower flexural rigidity compared to the intact tibiae of the contra-lateral leg indicating that the healing was not fully completed in both groups. While the intact tibiae showed a rigidity of  $133 \text{ Nm}^2$  ( $110\text{--}163 \text{ Nm}^2$ ), rigidity in the PRP group was  $3.41 \text{ Nm}^2$  ( $0\text{--}12.02 \text{ Nm}^2$ ) and in the control group  $2.45 \text{ Nm}^2$  ( $0.17\text{--}9.27 \text{ Nm}^2$ ). The difference between PRP and control animals was not statistically significant ( $p > 0.05$ ).

### 3.4. Bone volume and apparent mineral density

The apparent bone mineral density, which was measured by peripheral quantitative CT, did not differ significantly between the PRP (median  $280$ ,  $190\text{--}389 \text{ mg/cm}^3$ ) and the control group (median  $287$ ,  $221\text{--}406 \text{ mg/m}^3$ ). There were also no differences in the volume of the newly formed bone between the both groups. All defects showed substantial new bone formation but none had regenerated entirely. The median bone volume was  $2664 \text{ mm}^3$  ( $1073\text{--}8190 \text{ mm}^3$ ) in the PRP group and  $2900 \text{ mm}^3$  ( $1877\text{--}5072 \text{ mm}^3$ ) in the control group. The volume of newly formed bone in the defect strongly correlated with flexural rigidity ( $r_{\text{Sp}} 0.937$ ;  $p < 0.001$ ).

Since platelet concentration in the PRP varied from  $423$  to  $1695 \times 10^3/\mu\text{l}$  in individual animals, we examined if bone volume, apparent mineral density or rigidity were correlated with the individual platelet concentration. Neither bone volume ( $r_{\text{Sp}} 0.14$ ;  $p = 0.393$ ), nor mineral density ( $r_{\text{Sp}} -0.64$ ;  $p = 0.06$ ), nor rigidity ( $r_{\text{Sp}} -0.25$ ;  $p = 0.294$ ) correlated with platelet concentration in the PRP.

### 3.5. Histological results

Microscopically no residues of the collagen scaffold were found after 12 weeks. The gap between the osteotomized cortices was filled with newly formed bone, cartilage, and

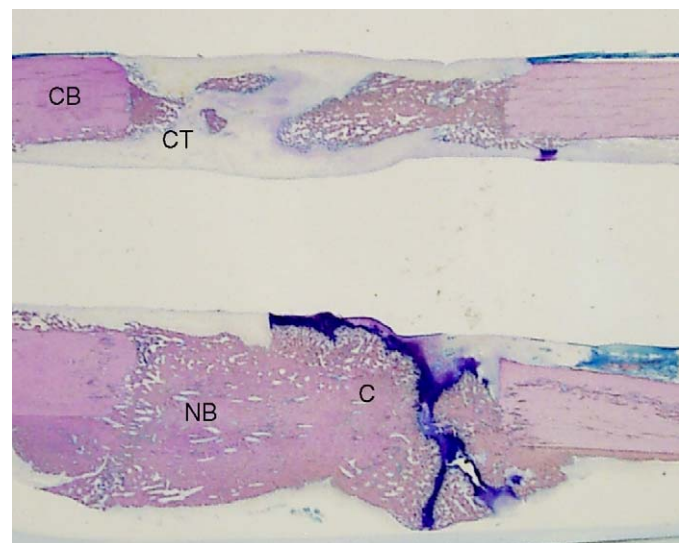


Fig. 4. Macroscopic histological picture of a longitudinal section through a bone defect (PRP-treated group). There were no significant differences between the groups regarding the amount and spacial distribution of newly formed bone (NB), cartilage (C) and connective tissue (CT). There was no periosteal callus formation on the medial side (top) because the plate was attached to the bone here. CB = cortical bone.

connective tissue (Fig. 4). There was no bone formation in the medullary cavity because there the nail had been implanted. The medial region of the defect between the intramedullary nail and the plate contained least amount of mineralized bone and was bridged in none of the animals. Along the osteotomy margins both resorption and new bone formation could be observed and intense remodelling was seen in the adjoining cortical bone. The relative amount of newly formed bone, cartilage and connective tissue in the different locations varied widely between the individual specimens. However, the median distribution of tissue types was similar for the PRP and the control defects. There were no significant differences between the groups (Table 1). Under fluorescent light it was apparent that large amounts of new bone had formed already after 4

weeks. Within the defect area both fluorescent dyes were present, indicating an ongoing remodelling process. Again, there was no difference in the spatial and temporal pattern of new bone formation between the groups (Fig. 5).

#### 4. Discussion

PRP in combination with a collagen type I scaffold did not increase de novo bone formation in a critical size defect in sheep tibia diaphysis. Bone volume, mineral density, and histology of the newly formed bone in the PRP defect did not differ from controls treated only with the collagen after a healing period of 12 weeks. There was also no influence on the chronology of bone formation as assessed by X-ray follow up and fluorochrome labelling. These results were confirmed by the biomechanical outcomes showing no differences in rigidity of PRP treated and untreated bones.




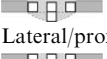

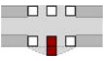
The clinical and experimental data in the literature regarding the osteogenic potential of PRP are controversial. A number of authors report a positive influence of

PRP on bone regeneration [7,13,18,23]. However, our results confirm a number of clinical [19,24,25] and experimental [12,26,27] studies demonstrating no effect of PRP on bone defect healing. In human maxillofacial defects, neither autograft nor allograft nor a mineral bone substitute material enhanced bone formation when augmented with PRP [19,24,25]. In a non-critical rabbit skull defect PRP was not superior to the empty defect nor did PRP increase bone formation by autogenous bone [12]. Likewise, in mandibular defects in minipigs, platelet-released growth factors did not stimulate bone formation [26,27].

Why are the results in the literature so controversial? PRP contains several growth factors, (e.g. isomers of PDGF, TGF- $\beta$ 1, TGF- $\beta$ 2, IGF-I, IGF-II and VEGF) all of which promote bone regeneration. PDGF was shown to be mitogenic for osteoblasts [28] and stimulated the migration of mesenchymal progenitor cells [29]. In animal defect models PDGF induced callus formation [15]. TGF- $\beta$  also has a stimulative effect on bone formation and inhibits

Table 1

Tissue composition (median, 25% and 75% quartiles) at different locations in the defect region (Fig. 1) of the PRP treated ( $n = 7$ ) and the control group ( $n = 7$ ) based on quantitative analysis of the undecalcified bone histology

Localization	Group	Bone	Cartilage	Fibrous tissue
Medial/proximal 	Control	46% (20–54)	0% (0–3)	54% (39–79)
	PRP	18% (5–48)	4% (2–12)	58% (52–71)
Medial/central 	Control	15% (5–21)	4% (0–11)	80% (65–96)
	PRP	12% (3–27)	13% (7–26)	65% (52–79)
Medial/distal 	Control	59% (42–71)	1% (0–2)	35% (29–57)
	PRP	52% (24–62)	0% (0–2)	48% (39–73)
Lateral/proximal 	Control	59% (42–76)	2% (2–8)	26% (21–34)
	PRP	48% (25–58)	25% (12–26)	43% (23–51)
Lateral/central 	Control	57% (15–73)	2% (0–5)	25% (16–44)
	PRP	41% (9–78)	0% (0–2)	54% (22–88)
Lateral/distal 	Control	74% (67–82)	2% (0–11)	21% (8–29)
	PRP	80% (73–85)	0% (0–0)	22% (15–28)

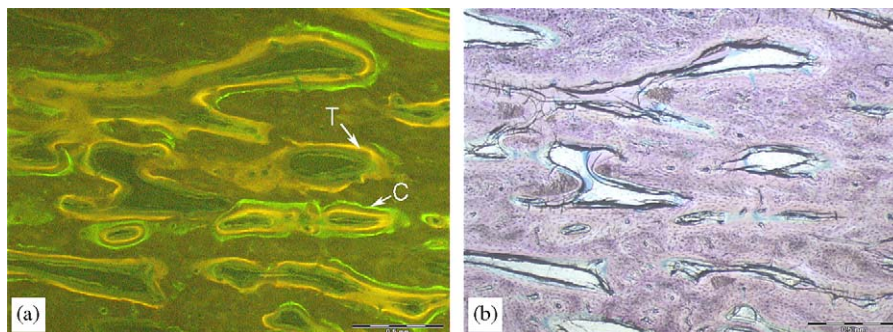


Fig. 5. (a) Characteristic distribution of the fluorescent dyes tetracycline (T, yellow) and calcein (C, green) in the central area of the defect (PRP-treated group). There were no significant differences between the groups regarding the amount and distribution of fluorochrome markers. (b) Corresponding light microscopy; bar = 0.5 mm.

bone resorption [30]. IGF-I and the angiogenic factor VEGF induced bone formation in rats [31] and in rabbits [32], respectively. In summary, these growth factors support bone regeneration primarily via chemotactic and mitogenic effects on preosteoblastic and osteoblastic cells. However, PRP does not contain BMPs, the most potent osteoinductive proteins, which promote stem cell differentiation into the osteoblastic lineage and are the only growth factors known to induce ectopic bone formation [33].

The reason for the failure of PRP in our and other studies might be that the potency of the growth factors liberated by PRP is too weak to induce bone formation in defects with low regenerative capacity. The bone defect in the present experiment was relatively large. The bone marrow containing a huge amount of mesenchymal precursor cells was removed by reaming the tibia before implanting the intramedullary nail, thus creating a defect situation with a low osteogenic potential, which was not entirely regenerated after 12 weeks in the control group despite implanting a collagen sponge. It most likely would not heal without any treatment as demonstrated in comparable critical size defects [34,35]. Whereas BMPs have been shown to induce bone healing in similar defect models [34], PRP was not able to enhance osteogenesis in our study. Clinical and animal studies that found positive effects for PRP were mostly performed in well-vascularized cancellous bone defects where an abundant presence of precursor cells can be assumed [7,20]. Some studies also used PRP in combination with autografts [7] or with a matrix with an additional intrinsic osteogenic effect [18,20]. It was assumed that PRP alone cannot induce bone formation but can support osteogenesis in the presence of precursors cells [18,19]. This may explain the success of PRP observed in cancellous defects or in combination with autogenous grafts. However, this limitation will prevent PRP from becoming an attractive alternative for the reconstruction of major diaphyseal defects with low regenerative potential.

One may argue that the lack of effect of PRP might also result from an insufficient platelet concentration. The growth factor content of PRP depends on the technique used for platelet concentration and the final thrombocyte count [36]. Because platelet size and density differ between sheep and humans, the protocol for PRP preparation was modified in the present study. Platelets were enriched on average 3.5 fold compared to normal blood, which was equivalent to studies reporting on positive effects with PRP [7,18]. In the present study, in some samples the platelet concentration was even increased up to 9-fold. However, we found no correlation between the individual platelet concentration in the PRP and new bone formation. Only few authors have investigated concentration-dependent effects. Schlegel et al. found somewhat better results with higher (6.5-fold compared to normal blood) than with lower platelet concentrations (4.1-fold) on bone regeneration in skull defects of minipigs [18,23]. Other experimental

studies found no correlation between the platelet concentration and the observed biological effects [12,20]. In the present study, even relatively high platelet concentrations were not effective.

## 5. Conclusions

In conclusion this study demonstrated that PRP could not promote bone regeneration in critical size defects with a low regenerative capacity. This limitation will prevent PRP from becoming an attractive alternative for the reconstruction of major diaphyseal defects in long bones. Such bone defects might require more potent stimuli, e.g. combinations of functional biomaterials or autografts, precursor cells or osteoinductive growth factors.

## Acknowledgements

We received valuable technical assistance by the animal research facility at Ulm University. Special thanks to Mr. H. Schmitt for designing the metallic implants and to Mrs. M. Tomo, Mrs. U. Maile and Mrs. P. Horny for technical assistance. The project was financed by the Center of Competence for Biomaterials, University of Ulm.

## References

- [1] Arrington ED, Smith WJ, Chambers HG, Bucknell AL, Davino NA. Complications of iliac crest bone graft harvesting. *Clin Orthop Relat Res* 1996;329:300–9.
- [2] Hollinger JO, Brekke J, Gruskin E, Lee D. Role of bone substitutes. *Clin Orthop Relat Res* 1996;324:55–65.
- [3] Bostrom MP, Saleh KJ, Einhorn TA. Osteoinductive growth factors in preclinical fracture and long bone defects models. *Orthop Clin North Am* 1999;30:647–58.
- [4] Reddi AH. Initiation of fracture repair by bone morphogenetic proteins. *Clin Orthop Relat Res* 1998;355:66–72.
- [5] Friedlaender GE, Perry CR, Cole JD, Cook SD, Cierny G, Muschler GF, et al. Osteogenic protein-1 (bone morphogenetic protein-7) in the treatment of tibial nonunions. *J Bone Joint Surg Am* 2001;83-A: 151–8.
- [6] Geesink RG, Hoefnagels NH, Bulstra SK. Osteogenic activity of OP-1 bone morphogenetic protein (BMP-7) in a human fibular defect. *J Bone Joint Surg Br* 1999;81:710–8.
- [7] Marx RE, Carlson ER, Eichstaedt RM, Schimmele SR, Strauss JE, Georgeff KR. Platelet-rich plasma: growth factor enhancement for bone grafts. *Oral Surg Oral Med Oral Pathol Oral Radiol Endod* 1998;85:638–46.
- [8] Weibrich G, Kleis WK, Hafner G, Hitzler WE. Growth factor levels in platelet-rich plasma and correlations with donor age, sex, and platelet count. *J Craniomaxillofac Surg* 2002;30:97–102.
- [9] McClain SA, Simon M, Jones E, Nandi A, Gailit JO, Tonnesen MG, et al. Mesenchymal cell activation is the rate-limiting step of granulation tissue induction. *Am J Pathol* 1996;149:1257–70.
- [10] Mustoe TA, Pierce GF, Morishima C, Deuel TF. Growth factor-induced acceleration of tissue repair through direct and inductive activities in a rabbit dermal ulcer model. *J Clin Invest* 1991;87: 694–703.
- [11] Saba AA, Freedman BM, Gaffield JW, Mackay DR, Ehrlich HP. Topical platelet-derived growth factor enhances wound closure in the absence of wound contraction: an experimental and clinical study. *Ann Plast Surg* 2002;49:62–6.

- [12] Aghaloo TL, Moy PK, Freymiller EG. Investigation of platelet-rich plasma in rabbit cranial defects: a pilot study. *J Oral Maxillofac Surg* 2002;60:1176–81.
- [13] Anitua E. Plasma rich in growth factors: preliminary results of use in the preparation of future sites for implants. *Int J Oral Maxillofac Implants* 1999;14:529–35.
- [14] Kassolis JD, Rosen PS, Reynolds MA. Alveolar ridge and sinus augmentation utilizing platelet-rich plasma in combination with freeze-dried bone allograft: case series. *J Periodontol* 2000;71:1654–61.
- [15] Nash TJ, Howlett CR, Martin C, Steele J, Johnson KA, Hicklin DJ. Effect of platelet-derived growth factor on tibial osteotomies in rabbits. *Bone* 1994;15:203–8.
- [16] Robiony M, Polini F, Costa F, Politi M. Osteogenesis distraction and platelet-rich plasma for bone restoration of the severely atrophic mandible: preliminary results. *J Oral Maxillofac Surg* 2002;60:630–5.
- [17] Rodriguez A, Anastassov GE, Lee H, Buchbinder D, Wettan H. Maxillary sinus augmentation with deproteinated bovine bone and platelet rich plasma with simultaneous insertion of endosseous implants. *J Oral Maxillofac Surg* 2003;61:157–63.
- [18] Schlegel KA, Donath K, Rupprecht S, Falk S, Zimmermann R, Felszeghy E, et al. De novo bone formation using bovine collagen and platelet-rich plasma. *Biomaterials* 2004;25:5387–93.
- [19] Froum SJ, Wallace SS, Tarnow DP, Cho SC. Effect of platelet-rich plasma on bone growth and osseointegration in human maxillary sinus grafts: three bilateral case reports. *Int J Periodont Restor Dent* 2002;22:45–53.
- [20] Kim SG, Kim WK, Park JC, Kim HJ. A comparative study of osseointegration of Avana implants in a demineralized freeze-dried bone alone or with platelet-rich plasma. *J Oral Maxillofac Surg* 2002;60:1018–25.
- [21] Augat P, Burger J, Schorlemmer S, Henke T, Peraus M, Claes L. Shear movement at the fracture site delays healing in a diaphyseal fracture model. *J Orthop Res* 2003;21:1011–7.
- [22] Augat P, Schorlemmer S, Gohl C, Iwabu S, Ignatius A, Claes L. Glucocorticoid-treated sheep as a model for osteopenic trabecular bone in biomaterials research. *J Biomed Mater Res A* 2003;66:457–62.
- [23] Thorwarth M, Rupprecht S, Falk S, Felszeghy E, Wiltfang J, Schlegel KA. Expression of bone matrix proteins during de novo bone formation using a bovine collagen and platelet-rich plasma (prp)—an immunohistochemical analysis. *Biomaterials* 2005;26:2575–84.
- [24] Shanaman R, Filstein MR, Danesh-Meyer MJ. Localized ridge augmentation using GBR and platelet-rich plasma: case reports. *Int J Periodont Restor Dent* 2001;21:345–55.
- [25] Raghoebar GM, Schortinghuis J, Liem RS, Ruben JL, van der Wal JE, Vissink A. Does platelet-rich plasma promote remodeling of autologous bone grafts used for augmentation of the maxillary sinus floor? *Clin Oral Implants Res* 2005;16:349–56.
- [26] Fuerst G, Gruber R, Tangl S, Sanroman F, Watzek G. Effects of fibrin sealant protein concentrate with and without platelet-released growth factors on bony healing of cortical mandibular defects: an experimental study in minipigs. *Clin Oral Implants Res* 2004;15:301–7.
- [27] Fuerst G, Reinhard G, Tangl S, Mittlbock M, Sanroman F, Watzek G. Effect of platelet-released growth factors and collagen type I on osseous regeneration of mandibular defects: a pilot study in minipigs. *J Clin Periodontol* 2004;31:784–90.
- [28] Assoian RK, Grotendorst GR, Miller DM, Sporn MB. Cellular transformation by coordinated action of three peptide growth factors from human platelets. *Nature* 1984;309:804–6.
- [29] Fiedler J, Roderer G, Gunther KP, Brenner RE. BMP-2, BMP-4, and PDGF-bb stimulate chemotactic migration of primary human mesenchymal progenitor cells. *J Cell Biochem* 2002;87:305–12.
- [30] Baylink DJ, Finkelman RD, Mohan S. Growth factors to stimulate bone formation. *J Bone Miner Res* 1993;8:565–72.
- [31] Spencer EM, Liu CC, Si EC, Howard GA. In vivo actions of insulin-like growth factor-I (IGF-I) on bone formation and resorption in rats. *Bone* 1991;12:21–6.
- [32] Street J, Bao M, deGuzman L, Bunting S, Peale Jr FV, Ferrara N, et al. Vascular endothelial growth factor stimulates bone repair by promoting angiogenesis and bone turnover. *Proc Natl Acad Sci USA* 2002;99:9656–61.
- [33] Cook SD. Preclinical and clinical evaluation of osteogenic protein-1 (BMP-7) in bony sites. *Orthopedics* 1999;22:669–71.
- [34] Gerhart TN, Kirker-Head CA, Kriz MJ, Holtrop ME, Hennig GE, Hipp J, et al. Healing segmental femoral defects in sheep using recombinant human bone morphogenetic protein. *Clin Orthop Relat Res* 1993;317–26.
- [35] Wippermann B, Donow C, Schratz HE, den Boer FC, Blokhuis T, Patka P. The influence of hydroxyapatite granules on the healing of a segmental defect filled with autologous bone marrow. *Ann Chir Gynaecol* 1999;88:194–7.
- [36] Marx RE. Platelet-rich plasma (PRP): what is PRP and what is not PRP? *Implant Dent* 2001;10:225–8.